

Effect of a Matrix Therapy Agent on Corneal Epithelial Healing After Standard Collagen Cross-linking in Patients With Keratoconus

A Randomized Clinical Trial

Ahmed M. Bata, MD; Katarzyna J. Witkowska, MD, PhD; Piotr A. Wozniak, MD; Klemens Fondi, MD; Gerald Schmidinger, MD; Niklas Pircher, MD; Stephan Szegedi, MD; Valentin Aranha dos Santos, MSc; Anca Pantalon, MD; René M. Werkmeister, PhD; Gerhard Garhofer, MD; Leopold Schmetterer, PhD; Doreen Schmidl, MD, PhD

IMPORTANCE Corneal abrasions are frequent after standard (epithelium-off [epi-off]) corneal collagen cross-linking (CXL) in patients with progressive keratoconus. A new matrix therapy agent (ReGeneraTing Agent [RGTA]) has been developed to promote corneal wound healing.

OBJECTIVE To assess the effect of the new type of matrix therapy agent on corneal wound healing after epi-off CXL in patients with keratoconus.

DESIGN, SETTING, AND PARTICIPANTS This double-masked randomized clinical trial enrolled 40 patients with keratoconus undergoing epi-off CXL from July 18, 2014, to October 21, 2015, when the last follow-up was completed. The analysis of the intention-to-treat population was performed at the Department of Clinical Pharmacology in cooperation with the Center for Medical Physics and Biomedical Engineering and the Department of Ophthalmology and Optometry of the Medical University of Vienna.

INTERVENTIONS Patients were randomized to receive the matrix therapy agent or hyaluronic acid-containing eyedrops, 0.1%, every other day starting immediately after surgery. The size of the corneal defect was measured using ultrahigh-resolution optical coherence tomography (OCT) and slitlamp photography (SLP) with fluorescein staining.

MAIN OUTCOMES AND MEASURES Corneal wound healing rate, defined as the size of the defect over time.

RESULTS Among the 40 patients undergoing epi-off CXL (31 men; 9 women; mean [SD] age, 31 [10] years), wound healing was significantly faster in the matrix therapy agent group compared with the hyaluronic acid group (4.4 vs 6.1 days; mean difference, 1.7 days; 95% CI, 0.25-3.15 days; $P = .008$). The defect size was smaller in the matrix therapy agent group than in the hyaluronic acid group as measured with OCT (12.4 vs 23.9 mm²; mean difference, 11.6 mm²; 95% CI, 0.8-23.5 mm²; $P = .045$) and SLP (11.9 vs 23.5 mm²; mean difference, 11.6 mm²; 95% CI, 1.3-22.9 mm²; $P = .03$). A correlation between the defect size measured with OCT and SLP was found ($r = 0.89$; $P < .001$). No ocular or serious adverse events occurred.

CONCLUSIONS AND RELEVANCE Use of a new matrix therapy agent appears to improve corneal wound healing after CXL in patients with keratoconus. Monitoring of corneal wound healing using ultrahigh-resolution OCT might be an attractive alternative to SLP because OCT provides an objective and 3-dimensional evaluation of the corneal defect.

TRIAL REGISTRATION clinicaltrials.gov Identifier: [NCT02119039](https://clinicaltrials.gov/ct2/show/study/NCT02119039)

JAMA Ophthalmol. 2016;134(10):1169-1176. doi:[10.1001/jamaophthalmol.2016.3019](https://doi.org/10.1001/jamaophthalmol.2016.3019)
Published online September 1, 2016.

← Invited Commentary
page 1176

+ Supplemental content at
jamaophthalmology.com

Author Affiliations: Department of Clinical Pharmacology, Medical University of Vienna, Vienna, Austria (Bata, Witkowska, Wozniak, Fondi, Szegedi, Garhofer, Schmetterer, Schmidl); Center for Medical Physics and Biomedical Engineering, Medical University of Vienna, Vienna, Austria (Witkowska, Aranha dos Santos, Werkmeister, Schmetterer, Schmidl); Department of Ophthalmology, Medical University of Warsaw, Warsaw, Poland (Wozniak); Department of Ophthalmology and Optometry, Medical University of Vienna, Vienna, Austria (Schmidinger, Pircher); Department of Ophthalmology, Grigore T. Popa University of Medicine and Pharmacy, Iasi, Romania (Pantalon).

Corresponding Author: Doreen Schmidl, MD, PhD, Department of Clinical Pharmacology, Medical University of Vienna, Waehringer Guertel 18-20, 1090 Vienna, Austria (doreen.schmidl@meduniwien.ac.at).

Corneal abrasions are among the most frequent eye injuries that can occur after trauma or surgery, in addition to iatrogenic injuries after general and ophthalmic procedures.¹⁻⁵ Common symptoms include pain, tearing, light sensitivity, eye redness, blurred vision, blepharospasm, and foreign-body sensation.¹ Depending on the area and depth of the epithelial defect, uncomplicated wound healing takes as long as 7 days, which corresponds to the reported turnover of the corneal epithelium.^{6,7} Inadequate wound healing can lead to complications ranging from corneal haze to perforation and blindness.⁶

Several therapeutic options for corneal abrasions are available, such as topical antibiotics, artificial tears, and topical lubricants.^{1,3} Systemic or topical nonsteroidal anti-inflammatory drugs or the insertion of a therapeutic soft contact lens might help to provide relief from pain, whereas in cases with accompanying traumatic iritis, cycloplegics may be used.^{1,8} Recently, a new type of matrix therapy agent (ReGeneraTing Agent [RGTA]) has been developed for topical ophthalmic use.⁹ This matrix therapy agent consists of large polymers that promote corneal wound healing by replacing destroyed heparan sulfate molecules required for corneal homeostasis.^{9,10} A formulation of matrix therapy agent eyedrops (Cacicol; Laboratoires Théa) has been approved for use in persistent corneal ulcers, and encouraging results have been obtained.^{9,11}

Corneal collagen cross-linking (CXL) is performed in patients with keratoconus to prevent further thinning and ectasia of the cornea. In theory, new covalent bounds between collagen fibrils of the corneal stroma are established through the application of riboflavin eyedrops combined with UV-A radiation treatment. The standard (epithelium-off [epi-off]) procedure is the most commonly performed technique and requires a debridement of the corneal epithelium, leading to a large corneal abrasion.¹²

In this double-masked, randomized clinical trial, we investigated the effect of matrix therapy agent eyedrops on corneal wound healing after epi-off CXL in patients with keratoconus. The rate of corneal wound healing was assessed by the following 2 independent methods: ultrahigh-resolution optical coherence tomography (OCT) and slitlamp photography (SLP) with fluorescein staining. In addition, subjective symptoms were assessed using visual analog scales (VASs).

Methods

The present study was performed in adherence to the Declaration of Helsinki¹³ and the Good Clinical Practice guidelines of the European Union. The study protocol (available in Supplement 1) was approved by the Ethics Committee of the Medical University of Vienna, Vienna, Austria, on March 12, 2014. The first patient was recruited on July 18, 2014, and the last patient completed follow-up for the study on October 21, 2015. All patients provided written informed consent.

Patients

Forty patients aged 18 to 55 years with progressive keratoconus scheduled for epi-off CXL in 1 eye were included. During

Key Points

Question Does a new matrix therapy agent improve corneal wound healing after standard corneal epithelium-off (epi-off) collagen cross-linking (CXL) in patients with keratoconus?

Findings In a randomized clinical trial of 40 patients with keratoconus scheduled for epi-off CXL, corneal wound healing was significantly faster in patients receiving matrix therapy agent-containing eyedrops compared with control individuals receiving hyaluronic acid-containing eyedrops.

Meaning Data from this study suggest that a matrix therapy agent improves corneal wound healing after standard corneal epi-off CXL in patients with keratoconus.

the 2 weeks before surgery, a screening examination was performed that included recording of the patient's medical history, a pregnancy test in women of childbearing potential, and a full ophthalmologic examination. In addition, SLP and ultrahigh-resolution OCT images of the cornea were obtained. Patients who had undergone ocular surgery in the previous 3 months, those with active ocular infection, or those who were going to use topical aminoglycoside antibiotics or contact lenses after surgery were not included in the study.

Study Design

The present study was performed in a double-masked, randomized design (Figure 1). The randomization list was created by computer software (<http://randomization.com>). On the day of surgery, patients were randomized to receive matrix therapy agent eyedrops (Cacicol) composed of poly(carboxymethylglucosulfate), dextran 40, sodium chloride, and purified water, or control eyedrops (GenTeal HA; Laboratoires Théa), composed of hyaluronic acid (sodium hyaluronate), 0.1%, sodium chloride, sodium phosphate, and sodium perborate, after epi-off CXL. The first dose was given after surgery and then every 2 days until the epithelial wound was closed. Instillation of the eyedrops was performed by a physician not involved in the study-related procedures, and patients were not informed of the treatment to which they were randomized, to obtain double-masked conditions.

Patients returned to the department every 2 days, where a slitlamp examination and imaging of the cornea using ultrahigh-resolution OCT was performed. In addition, SLP was obtained and pain was assessed using the VAS. If corneal abrasion was still visible at the slitlamp examination after fluorescein instillation, patients received treatment according to their randomization. Patients underwent assessment every 2 days until corneal epithelial wound closure was achieved. A final examination was performed 7 to 14 days after wound closure was observed, when the abovementioned procedures were repeated.

Procedures

Surgical Technique

Accelerated epi-off CXL was performed under sterile conditions. Briefly, after topical anesthesia, mechanical abrasion of

a standardized diameter of 10.0 mm was performed and riboflavin eyedrops (VibeX Rapid; Avedro, Inc) were administered topically every 2 minutes for 10 minutes. Next, UV-A irradiation was performed for 10 minutes using an illumination system with a power of 9 mW/cm² (UVX-2000; Avedro, Inc). After surgery, all patients received standardized preservative-free treatments that included topical ofloxacin (Ofloxacin Vision Sine; OmniVision) and dexamethasone (Monodex, Laboratoires Thea) 3 times daily.

Assessment of Corneal Wound Healing

Using Ultrahigh-Resolution OCT

Corneal wound healing was assessed with a custom-built ultrahigh-resolution OCT system described previously.¹⁴ This system used Ti:sapphire laser with a central wavelength of 800 nm and a spectral bandwidth of 170 nm. The theoretical axial resolution of the device is 1.2 μ m in corneal tissue, whereas the lateral resolution given by the focusing optics is approximately 18 μ m. The incident power of the probe beam onto the cornea was set to 1.5 mW for acquisition of the corneal volumes to measure the epithelial wound. This value is well below the maximum permissible exposure as specified by the American National Standards Institute¹⁵ and International Electrotechnical Commission.¹⁶

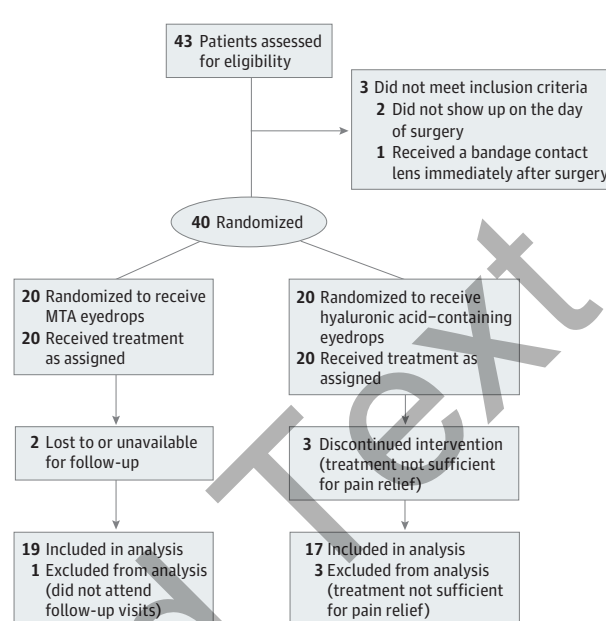
During the alignment procedure of the instrument in front of the eye, patients were asked to blink normally. For evaluation of corneal wound healing, 1 OCT volume with a size of 7.5 \times 7.5 \times 1 mm (horizontal \times vertical \times depth) and consisting of 1024 \times 512 \times 1024 pixels was recorded within 5 seconds. After the first postprocessing steps, including rescaling and dispersion compensation, the acquired volumes were resectioned in the axial direction to obtain an en face image of the anterior cornea. The borders of the corneal erosion were segmented (eFigure in Supplement 2) using custom software written in LabView (version 2013; National Instruments). To obtain an absolute measure for the wound area, first, the scanning range of the OCT system was taken into account. In a second step, the distortion of the en face image due to the curvature of the cornea was corrected, assuming a radius of 7.8 mm for the anterior corneal surface.¹⁷

Assessment of Corneal Wound Healing

Using SLP With Fluorescein Staining

For evaluation of the healing process after epi-off CXL, we performed SLP with fluorescein staining (Figure 2). To this end, fluorescein sodium drops, 2.0% (Minims; Chauvin Pharmaceuticals, Ltd), were instilled in the study eye, and photographs were obtained under illumination with cobalt-blue light using a standard slitlamp (BQ 900; Haag Streit AG) and a digital camera. The area of corneal abrasion was measured semi-automatically with a custom macro written for ImageJ (National Institutes of Health; available in the public domain at <https://rsbweb.nih.gov/ij/>). The stained corneal wound was segmented based on the analysis of the image histogram. Thereafter, the patient's iris was detected via application of edge filtering to the fluorescein SLP, and its diameter and area were calculated. Finally, the time course of the wound healing was evaluated by calculating the ratio of the corneal wound area to the iris area (including the pupil).

Figure 1. Study Flowchart



One of the 2 patients lost to follow-up in the matrix therapy agent (MTA) group attended the day 2 postoperative visit and was included in the per protocol analysis.

Visual Analog Scale

An ocular discomfort score was determined using a 100-mm VAS, on which 0 means no symptoms and 100 means the worst possible discomfort. Patients were asked to evaluate foreign-body sensation, burning, itching, and sticky feeling.

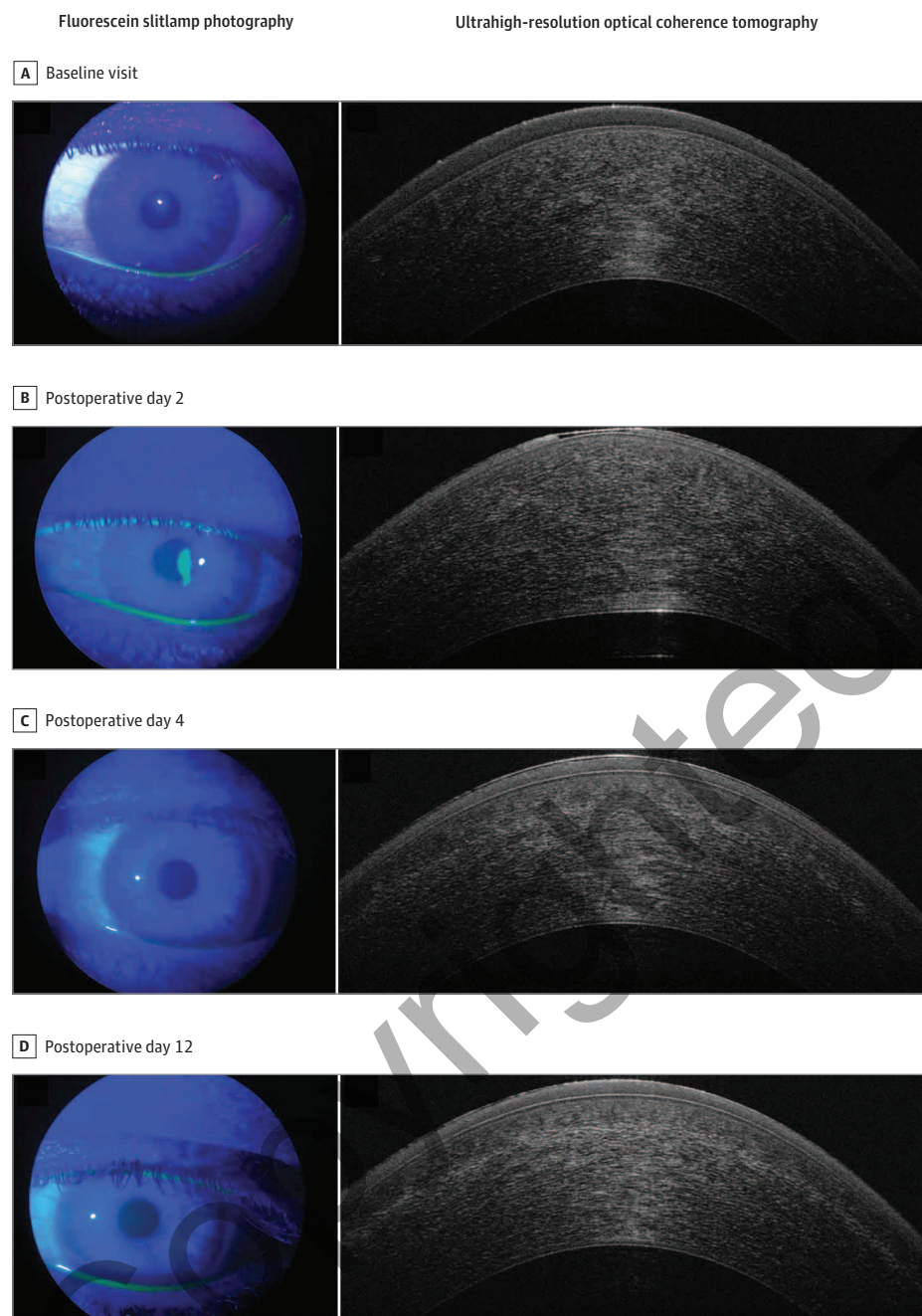
Statistical Analysis

Statistical analysis was performed on an intention-to-treat basis. To detect differences in the time course of the epithelial defects and VAS scores between treatments, we applied a 2-way repeated-measures Friedman analysis of variance model. All patients who attended the postoperative day 2 visit were included in the per protocol analysis. Differences in the time to total healing were assessed with unpaired *t* tests. We analyzed the correlation between the defect size as obtained with OCT and SLP using linear regression analysis. Data are presented as means (95% CI) except for ocular discomfort scores, which are presented as medians (95% CI). In addition, we generated Bland-Altman plots for the defect size data. All statistical analysis was performed using CSS Statistica software (version 6.0; StatSoft, Inc). All variables were prespecified. No post hoc analyses were performed.

Results

A total of 40 patients aged 18 to 55 years with keratoconus scheduled for corneal epi-off CXL in 1 eye were included in the present study (31 men [78%]; 9 women [22%]; mean [SD] age, 31 [10] years). Of those 40 patients, 34 finished the study according to the protocol. One patient who was in the

Figure 2. Fluorescein Slitlamp Photographs and Ultrahigh-Resolution Optical Coherence Tomography Images



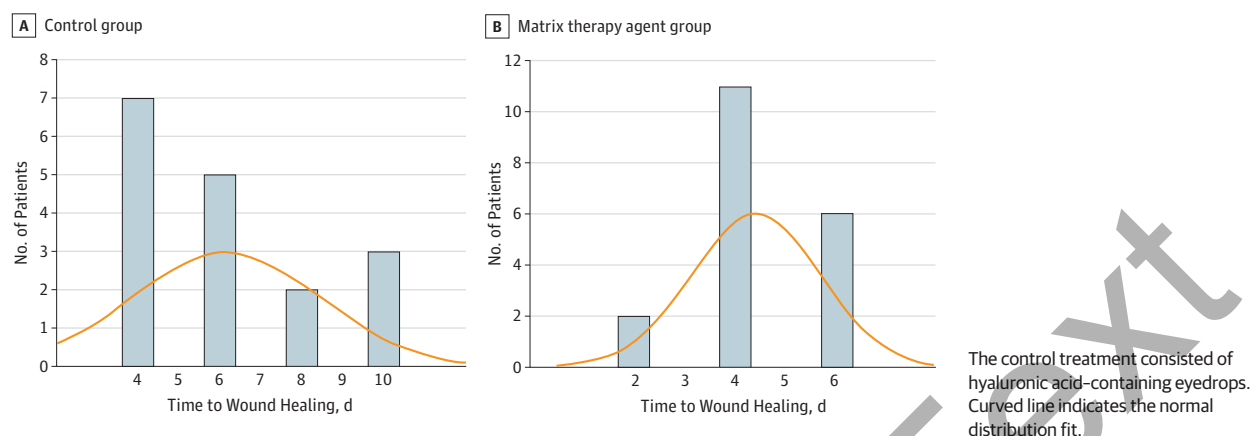
Images were obtained from patient 15, who was randomized to the matrix therapy agent group.

matrix therapy agent group did not attend the follow-up visits and was excluded from analysis. Another patient in the matrix therapy agent group attended the postoperative day 2 visit but not the later visits, and was included in the analysis. Three patients had to be excluded because they found the study treatment to be insufficient for pain relief, and a therapeutic contact lens was inserted before the day 2 visit. Unmasking after the end of the study revealed that all 3 patients had been randomized to the control treatment, and none of these patients were included in the analysis. One patient in the matrix therapy agent group had to be

excluded from OCT analysis because no measurements with the OCT system could be obtained. However, the patient remained in the SLP analysis. No ocular or serious adverse event was observed during the course of the study. The study flowchart is shown in Figure 1.

Sex distribution was similar among both groups. Mean (SD) age was 31.4 (11.0) years in the matrix therapy agent group and 29.5 (8.4) years in the control group. Wound healing was significantly faster in the matrix therapy agent group compared with the control group. The mean healing time was 6.1 days in the control group, whereas it was 4.4

Figure 3. Mean Time to Complete Wound Healing



days in the matrix therapy agent group. The difference in mean healing time was 1.7 days (95% CI, 0.25-3.15 days; $P = .008$, Friedman analysis of variance) (Figure 3). The time course of the defect size is presented in Figure 4. The defect size was smaller in the matrix therapy agent group, and this effect was already observed on day 2 using OCT (12.4 vs 23.9 mm²; mean difference, 11.6 mm²; 95% CI, 0.8-23.5 mm²; $P = .045$) and SLP (11.9 vs 23.5 mm²; mean difference, 11.6 mm²; 95% CI, 1.3-22.9 mm²; $P = .03$). No differences were observed between groups in terms of VAS scores (eTable in Supplement 2). In general, VAS scores were low from day 4 after surgery and beyond. At day 2, some symptoms were less pronounced in the matrix therapy agent group compared with the control group.

Linear correlation analysis revealed excellent agreement between the defect size as measured with OCT and fluorescein SLP ($r = 0.89$; $P < .001$) (Figure 5). In accord with this finding, the Bland-Altman plots show only minor differences between the techniques, although slightly larger areas were measured using OCT.

Discussion

In the present study, corneal wound healing after epi-off CXL was significantly faster when matrix therapy agent eyedrops were applied compared with hyaluronic acid-containing eyedrops. This finding was confirmed using 2 different methods for assessment of lesion size. In the matrix therapy agent group, 4.4 days were required for wound closure, which is comparable to findings of a similar study performed by Kymionis et al,¹⁸ in which 61.1% of corneal wounds were healed after 3 days and 100% after 4 days in eyes that had received the matrix therapy agent after epi-off CXL for keratoconus. The treatment regimen in their study, was, however, different than the one used in the present study because they applied matrix therapy agent eyedrops once daily in combination with a bandage contact lens until full reepithelization was achieved. In addition, patients in the previous study were encouraged to use artificial tears 6 times a day, whereas matrix therapy agent was

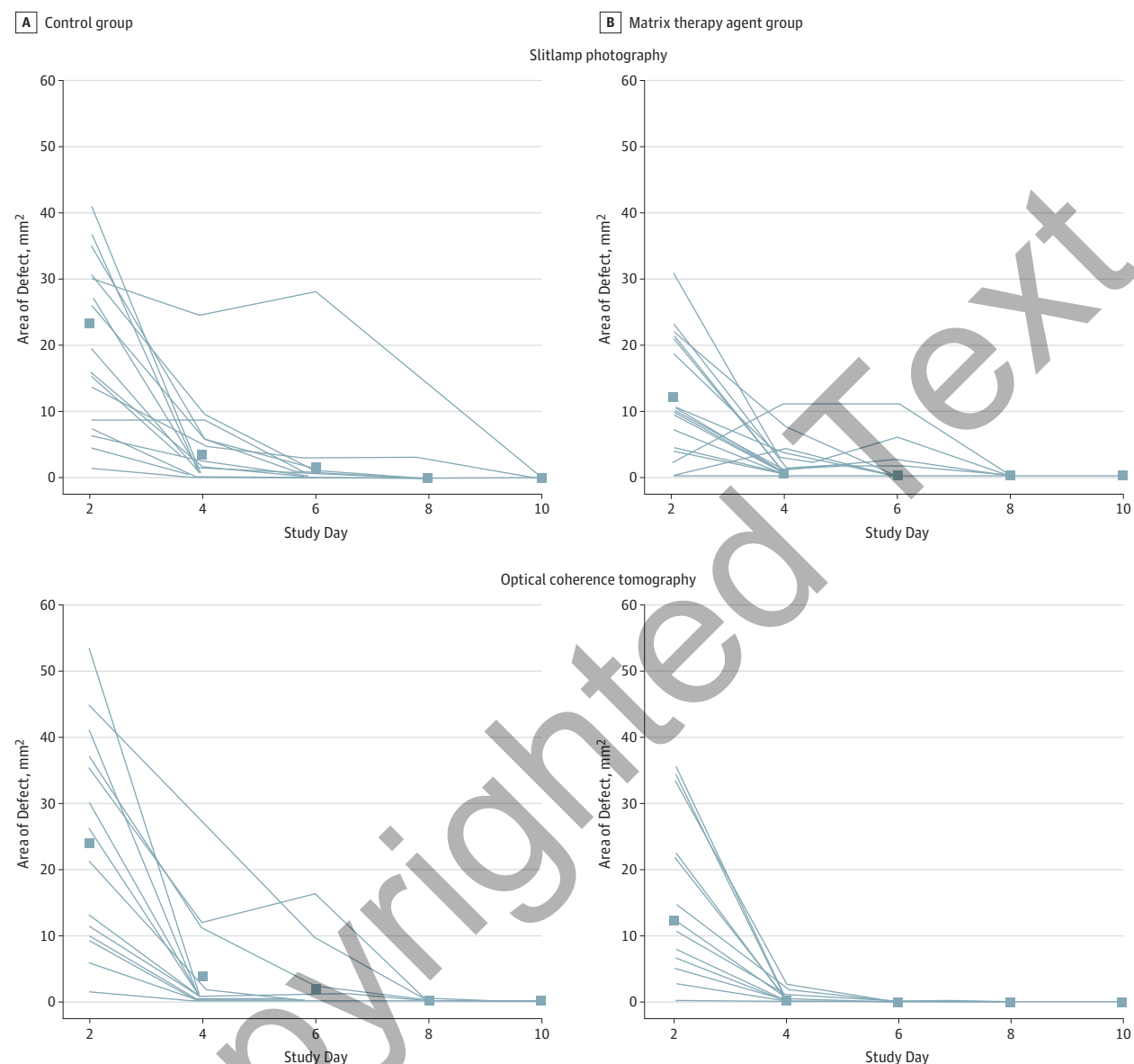
instilled every other day in the study group in the present trial without any concomitant topical lubricants or bandage contact lenses. Our findings indicate that matrix therapy agent eyedrops alone are effective in promoting corneal wound healing when applied every other day.

The matrix therapy agent promotes wound repair by mimicking destroyed heparan sulfate, which plays a key role in the healing process.⁹ Heparan sulfate is necessary for the cell-to-cell and the cell-to-extracellular matrix interactions.¹⁹ Furthermore, heparan sulfate acts as an endogenous receptor for several extracellular ligands, growth factors, and chemokines, thereby regulating cell proliferation and differentiation.¹⁹ Preclinical studies using matrix therapy agent in rabbit corneas found similar beneficial effects on corneal wound healing.^{20,21} These positive effects have also been observed in patients with chronic neurotrophic ulcers or severe corneal dystrophies.^{9,22,23} The treatment regimen ranged from daily application to instillation only once a week; nevertheless, no ideal instillation frequency has been determined.^{9,11,22} Too frequent use, however, seems to compromise the healing effect of the matrix therapy agent by competing with heparan-binding growth factors when all binding sites are occupied.^{23,24}

In the present study, we used 2 independent techniques for assessment of corneal wound healing. Measurement of lesion size with the slitlamp using fluorescein has been applied in several studies.^{8,18,25,26} Most of those investigators, however, only measured the diameter of the defect with the scale of the slitlamp, which is dependent on several factors, such as distance and refractive error of the examiner. To overcome these problems, we graded the corneal defect size based on fluorescein SLP and used the ratio of the defect area to the area of iris as the variable. However, fluorescein assessment of corneal epithelial damage is only 2-dimensional.

We therefore also used ultrahigh-resolution OCT imaging of the cornea, which has the advantage of obtaining volumes of the defect size. This custom-built system provides an axial resolution of 1.2 μm and has been used in several studies for assessment of precorneal tear film thickness,

Figure 4. Change in Area of Defect After Treatment



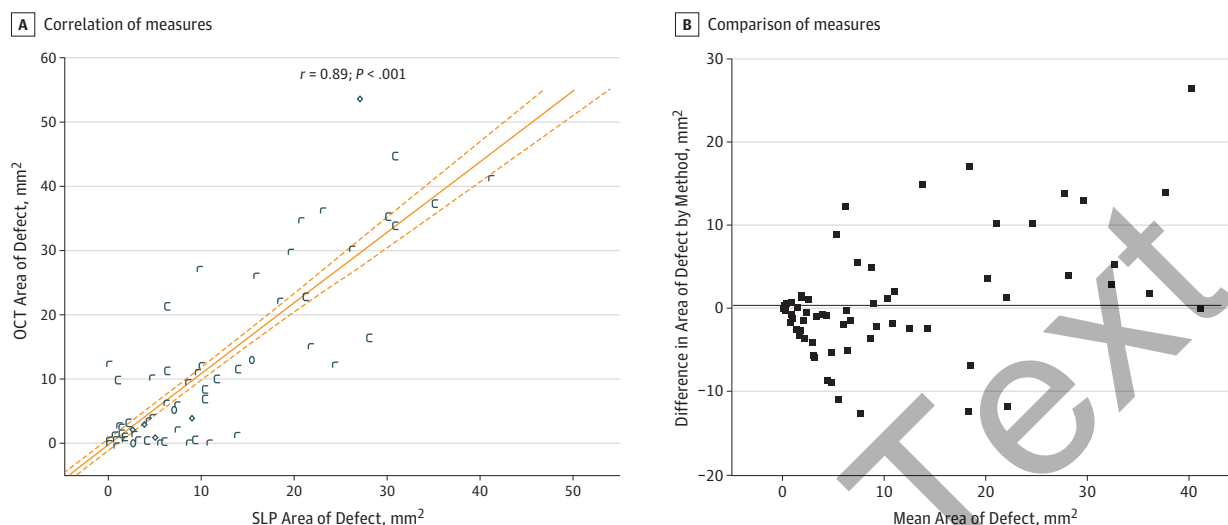
The control treatment consisted of hyaluronic acid-containing eyedrops. Data were separately measured using slitlamp photography after fluorescein staining or optical coherence tomography. Squares indicate mean area of defect; lines, individual patients.

which provides excellent reproducibility.^{14,27-29} In the present study, we have shown that this technique can also be used for measurements of corneal epithelial defects, and the correlation with the assessments performed from fluorescein photographs was very strong. The same correlation was found in a study conducted by Chen et al³⁰ in which ultrahigh-resolution OCT imaging for monitoring of corneal epithelial healing after pterygium surgery was used and compared with fluorescein staining. Those authors also found that the technique can be used easily when bandage contact lenses are inserted.³⁰ Because fluorescein should not be used with soft contact lenses inserted, this technique could provide a large advantage in the follow-up of corneal

epithelial wounds after several surgical procedures or when therapeutic contact lenses should not be removed for a longer period, which is the case in several forms of keratopathy.^{31,32} In addition, Figure 2 indicates that OCT technology is capable of visualizing the demarcation line in the stroma after epi-off CXL. In the present study, however, we did not quantify the volume of the stroma that was affected.

A strength of the present study is that all administered drugs, including antibiotics and nonsteroidal anti-inflammatory drugs, were free of preservatives. This distinction is important because preservatives such as benzalkonium chloride may well affect corneal wound healing. This

Figure 5. Correlation and Comparison of Area of Defect



A, Correlation between the area of defect as measured using slitlamp photography (SLP) after fluorescein staining and ultrahigh-resolution optical coherence tomography (OCT). Solid line indicates the regression line; dotted lines, 95% CI. B, Bland-Altman plot compares the area of the defect as measured using SLP after fluorescein staining and OCT. Horizontal line indicates the mean difference between OCT and SLP. Data points indicate individual patients.

effect is mediated by detergent but also by toxic effects, which have been described in the literature in some detail.³³

Our study also had some limitations. We used hyaluronic acid-containing eyedrops instilled every other day as a control, whereas, in clinical practice, topical lubricants are used far more frequently, such as 4 to 6 times daily. Common treatments for corneal abrasion after epi-off CXL include the insertion of bandage contact lenses or the frequent use of topical lubricants.³⁴⁻³⁶ However, because we aimed to obtain double-masked conditions, we decided against the use of these options. As such, 3 patients did not complete the study and were treated independently of the study objective.

Conclusions

Matrix therapy agent eyedrops seem to improve corneal wound healing after epi-off CXL in patients with keratoconus and might provide a valuable alternative to bandage contact lenses in the future. In addition, matrix therapy agents could be used in other forms of iatrogenic or traumatic abrasions, which will require further investigation. Monitoring of corneal wound healing using ultrahigh-resolution OCT seems to be an attractive alternative to fluorescein staining because it provides an objective and 3-dimensional evaluation of the corneal defect.

ARTICLE INFORMATION

Accepted for Publication: June 28, 2016.

Published Online: September 1, 2016.
doi:10.1001/jamaophthalmol.2016.3019.

Author Contributions: Drs Schmetterer and Schmidl had full access to all the data in the study and take responsibility for the integrity of the data and the accuracy of the data analysis.

Study concept and design: Bata, Witkowska, Werkmeister, Garhofer, Schmetterer, Schmidl.

Acquisition, analysis, or interpretation of data: Bata, Witkowska, Wozniak, Fondi, Schmidinger, Pircher, Szegedi, Aranha dos Santos, Pantalon, Werkmeister, Schmetterer, Schmidl.

Drafting of the manuscript: Bata, Pantalon, Werkmeister, Garhofer, Schmidl.

Critical revision of the manuscript for important intellectual content: Bata, Witkowska, Wozniak, Fondi, Schmidinger, Pircher, Szegedi, Aranha dos Santos, Pantalon, Schmetterer, Schmidl.

Statistical analysis: Aranha dos Santos, Garhofer, Schmetterer, Schmidl.

Obtained funding: Schmidl.

Administrative, technical, or material support: Bata, Fondi, Schmidinger, Pircher, Szegedi, Aranha dos

Santos, Pantalon, Werkmeister, Garhofer.
Study supervision: Witkowska, Werkmeister, Schmetterer, Schmidl.

Conflict of Interest Disclosures: All authors have completed and submitted the ICMJE Form for Disclosure of Potential Conflicts of Interest. Drs Garhofer and Schmetterer report receiving grants, speakers fees, and consultancy fees from Laboratoires Thea. No other disclosures were reported.

Funding/Support: This study was supported by Hochschuljubiläumsstiftung der Stadt Wien (project H-289408/2013). Thea Pharma provided the study drugs.

Role of the Funder/Sponsor: The funding sources had no role in the design and conduct of the study; collection, management, analysis, and interpretation of the data; preparation, review, or approval of the manuscript; and decision to submit the manuscript for publication.

REFERENCES

1. Wipperman JL, Dorsch JN. Evaluation and management of corneal abrasions. *Am Fam Physician*. 2013;87(2):114-120.

2. Sampat A, Parakati I, Kunnavakkam R, et al. Corneal abrasion in hysterectomy and prostatectomy: role of laparoscopic and robotic assistance. *Anesthesiology*. 2015;122(5):994-1001.

3. Segal KL, Fleischut PM, Kim C, et al. Evaluation and treatment of perioperative corneal abrasions. *J Ophthalmol*. 2014;2014:901901.

4. Holzman A, LoVerde L. Effect of a hyperosmotic agent on epithelial disruptions during laser in situ keratomileusis. *J Cataract Refract Surg*. 2015;41(5):1044-1049.

5. Ivarsen A, Asp S, Hjortdal J. Safety and complications of more than 1500 small-incision lenticule extraction procedures. *Ophthalmology*. 2014;121(4):822-828.

6. Lin T, Gong L. Sodium hyaluronate eye drops treatment for superficial corneal abrasion caused by mechanical damage: a randomized clinical trial in the People's Republic of China. *Drug Des Dev Ther*. 2015;9:687-694.

7. Bron AJ, Argüeso P, Irkeç M, Bright FV. Clinical staining of the ocular surface: mechanisms and interpretations. *Prog Retin Eye Res*. 2015;44:36-61.

8. Menghini M, Knecht PB, Kaufmann C, et al. Treatment of traumatic corneal abrasions: a three-arm, prospective, randomized study. *Ophthalmic Res*. 2013;50(1):13-18.
9. Aifa A, Gueudry J, Portmann A, Delcampe A, Muraine M. Topical treatment with a new matrix therapy agent (RGTA) for the treatment of corneal neurotrophic ulcers. *Invest Ophthalmol Vis Sci*. 2012;53(13):8181-8185.
10. Coulson-Thomas VJ, Chang SH, Yeh LK, et al. Loss of corneal epithelial heparan sulfate leads to corneal degeneration and impaired wound healing. *Invest Ophthalmol Vis Sci*. 2015;56(5):3004-3014.
11. Kymionis GD, Liakopoulos DA, Grentzelos MA, et al. Combined topical application of a regenerative agent with a bandage contact lens for the treatment of persistent epithelial defects. *Cornea*. 2014;33(8):868-872.
12. Farjadnia M, Naderan M. Corneal cross-linking treatment of keratoconus. *Oman J Ophthalmol*. 2015;8(2):86-91.
13. World Medical Association. World Medical Association Declaration of Helsinki: ethical principles for medical research involving human subjects. *JAMA*. 2013;310(20):2191-2194. doi:10.1001/jama.2013.281053.
14. Werkmeister RM, Alex A, Kaya S, et al. Measurement of tear film thickness using ultrahigh-resolution optical coherence tomography. *Invest Ophthalmol Vis Sci*. 2013;54(8):5578-5583.
15. American National Standards Institute. *American National Standard for Safe Use of Lasers*. Orlando, FL: Laser Institute of America; 2000. Publication Z136.1-2000
16. Austrian Electrotechnical Association. Sicherheit von Lasereinrichtungen—Teil 1: Klassifizierung von Anlagen und Anforderungen (ÖVE/ÖNORM EN 60825-1:2015-08-01). 2014. https://www.ove.at/webshop/artikel/1f0569c3ca-ove-onorm-en-60825-1-2015-08-01.html?lang=en_US. Revised August 1, 2015. Accessed July 1, 2014.
17. Gullstrand A. The dioptrics of the eye. In: Southall J, ed. *Helmholtz's Treatise on Physiological Optics*. Vol 1. Rochester, NY: Optical Society of America; 1924:351-352.
18. Kymionis GD, Liakopoulos DA, Grentzelos MA, et al. Effect of the regenerative agent poly(carboxymethylglucose sulfate) on corneal wound healing after corneal cross-linking for keratoconus. *Cornea*. 2015;34(8):928-931.
19. Olczyk P, Mencner Ł, Komosińska-Vashev K. Diverse roles of heparan sulfate and heparin in wound repair. *Biomed Res Int*. 2015;2015:549417.
20. Alcalde I, Iñigo-Portugués A, Carreño N, Riestra AC, Merayo-Llones JM. Effects of new biomimetic regenerating agents on corneal wound healing in an experimental model of post-surgical corneal ulcers. *Arch Soc Esp Oftalmol*. 2015;90(10):467-474.
21. Brignole-Baudouin F, Warnet JM, Barritault D, Baudouin C. RGTA-based matrix therapy in severe experimental corneal lesions: safety and efficacy studies. *J Fr Ophthalmol*. 2013;36(9):740-747.
22. Chebbi CK, Kichenin K, Amar N, et al. Pilot study of a new matrix therapy agent (RGTA OTR4120) in treatment-resistant corneal ulcers and corneal dystrophy [in French]. *J Fr Ophthalmol*. 2008;31(5):465-471.
23. Hughes L, Lockington D, Mantry S, Ramaesh K. Novel matrix ReGeneraTing Agent promotes rapid corneal wound healing. *Clin Experiment Ophthalmol*. 2015;43(4):391-392.
24. Pison A, Hay A, Dethorey G, Brezin A, Bourges JL. Healing of a resistant corneal neurotrophic ulcer using a new matrix therapy agent (RGTA). *Acta Ophthalmol*. 2013;91(suppl s252). doi:10.1111/j.1755-3768.2013.1631.x.
25. Aslanides IM, Selimis VD, Bessis NV, Georgoudis PN. A pharmacological modification of pain and epithelial healing in contemporary transepithelial all-surface laser ablation (ASLA). *Clin Ophthalmol*. 2015;9:685-690.
26. Chung JH. Correlation between epithelial healing rate and initial wound size in contact lens-induced central epithelial abrasion. *Ophthalmologica*. 1998;212(1):46-49.
27. Kaya S, Schmidl D, Schmetterer L, et al. Effect of hyaluronic acid on tear film thickness as assessed with ultra-high resolution optical coherence tomography. *Acta Ophthalmol*. 2015;93(5):439-443.
28. Schmidl D, Witkowska KJ, Kaya S, et al. The association between subjective and objective parameters for the assessment of dry-eye syndrome. *Invest Ophthalmol Vis Sci*. 2015;56(3):1467-1472.
29. Schmidl D, Schmetterer L, Witkowska KJ, et al. Tear film thickness after treatment with artificial tears in patients with moderate dry eye disease. *Cornea*. 2015;34(4):421-426.
30. Chen D, Lian Y, Li J, Ma Y, Shen M, Lu F. Monitor corneal epithelial healing under bandage contact lens using ultrahigh-resolution optical coherence tomography after pterygium surgery. *Eye Contact Lens*. 2014;40(3):175-180.
31. Kanpolat A, Uçakhan OO. Therapeutic use of Focus Night & Day contact lenses. *Cornea*. 2003;22(8):726-734.
32. Rubinstein MP. Applications of contact lens devices in the management of corneal disease. *Eye (Lond)*. 2003;17(8):872-876.
33. Baudouin C, Labbé A, Liang H, Pauly A, Brignole-Baudouin F. Preservatives in eyedrops: the good, the bad and the ugly. *Prog Retin Eye Res*. 2010;29(4):312-334.
34. Dhawan S, Rao K, Natrajan S. Complications of corneal collagen cross-linking. *J Ophthalmol*. 2011;2011:869015.
35. Bouheraoua N, Jouve L, Borderie V, Laroche L. Three different protocols of corneal collagen crosslinking in keratoconus: conventional, accelerated and iontophoresis [published online November 12, 2015]. *J Vis Exp*. 2015;(105). doi:10.3791/53119.
36. Seyedian MA, Aliakbari S, Mirafshar M, Hashemi H, Asgari S, Khabazkhoob M. Corneal collagen cross-linking in the treatment of progressive keratoconus: a randomized controlled contralateral eye study. *Middle East Afr J Ophthalmol*. 2015;22(3):340-345.

Invited Commentary

Abrasions, Planned Defects, and Persistent Epithelial Defects in Corneal Epithelial Wound Healing

Bennie H. Jeng, MD

Corneal epithelial wound healing is a seemingly simplistic process that in reality is quite complex depending on the circumstances: the proliferation, migration, and adhesion of epithelial cells occur differently under various conditions of inflammation, infection, and underlying stromal processes. As such, therapies to heal traumatic corneal abrasions, planned corneal epithelial defects such as postphotorefractive keratectomy (PRK), and persistent epithelial defects (PED) may require addressing different mechanisms. Because of the possible consequences of

epithelial defects, such as infection, scarring, corneal melting, and even perforation, all potentially leading to loss of vision, interest in healing corneal epithelial defects is high.

Traumatic corneal abrasions are typically at the highest risk for infection, and treatment involves prophylaxis and careful observation for the development of infectious processes as well as monitoring for progression to nonhealing states. Planned corneal epithelial defects such as post-PRK are usually in relatively healthy corneas under clean conditions, and these defects are generally expected to heal without incident, although these defects can become infected or even nonhealing.



Related article page 1169